



PATIENT

Princess Becerra

PRESENTING CLINICAL SIGNS

History: H/O mild to moderate MR and TR. Stable on recent echocardiogram (5/2021).

H/O SVT; routine recheck holter to assess control.

Current medications: Vetmedin 10mg 1 BID, Diltiazem 60mg 1.5 every 8 hrs

Prior holter results (2/21 MML) BBB morphology, 2 VPCs, single escape, occ APCs with parox SVT

SPECIES

Canine

HOLTER MONITOR FINDINGS AND RHYTHM ASSESSMENT

BREED

Pit Bull Mix

Time analyzed	23:19h
Mean heart rate	58bpm
Maximum heart rate	250bpm
Minimum heart rate	30bpm
VPCs	5
APCs	46; 25 singles, 3 runs

SEX

FS

AGE

2014

Interpretation: Underlying normal sinus rhythm with appropriate rate variation persists. QRS is wide consistent with a bundle branch block/short PR as previously documented. Isolated (5) VPCs and a single escape following a sinus pause. Occasional APCs with 2 paroxysms of SVT; HR 200-240bpm.

WEIGHT

72 lbs

Rhythm diagnosis: Sinus rhythm with paroxysmal SVT; apparently well controlled. Occasional ventricular ectopy. BBB.

INTERPRETED BY

Maggie Machen Lamy,
DVM, DACVIM
(Cardiology)

RECOMMENDATIONS

Persistently good control is seen here. Brief rare SVT with occasional premature beats. No significant change from the prior recording.

No changes to the medications are indicated at this time. Should the patient experience any related clinical signs in the future (acute lethargy, syncope), consider change to Sotalol at that time. Unfortunately even with apparently good control the patient will always be at risk for break through arrhythmias, syncope and/or sudden death.

IMAGING PERFORMED BY

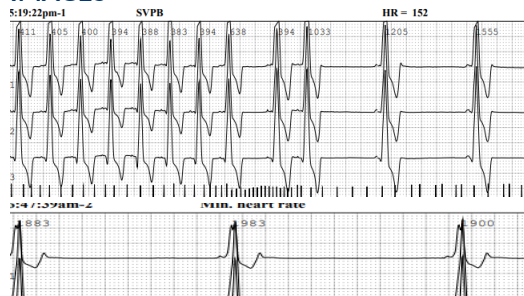
Mild activity restriction is advised lifelong.

Reassess a holter every 6-12months, or should symptoms develop in the future.

HOSPITAL NAME

Englewood Vet Center

IMAGES



Brief SVT

BBB

REFERRING VET

Dr. Ezik

INVOICE

21428

The information and recommendations provided are based on the images presented by the referring veterinarian. No evaluation can be communicated regarding pathology that was not visible in the image/video clips provided.

DATE

10/8/21

Thank you for this referral. If the clinical or image interpretation does not parallel your findings or if I



PATIENT

can be of any further assistance please contact me.

Princess Becerra

Maggie Machen Lamy, DVM

Diplomate of the American College of Veterinary Internal Medicine (Cardiology)

info@sonopath.com

SPECIES

Canine

BREED

Pit Bull Mix

SEX

FS

AGE

2014

WEIGHT

72 lbs

INTERPRETED BY

Maggie Machen Lamy,
DVM, DACVIM
(Cardiology)

**IMAGING
PERFORMED BY**

HOSPITAL NAME

Englewood Vet
Center

REFERRING VET

Dr. Ezik

INVOICE

21428

DATE

10/8/21